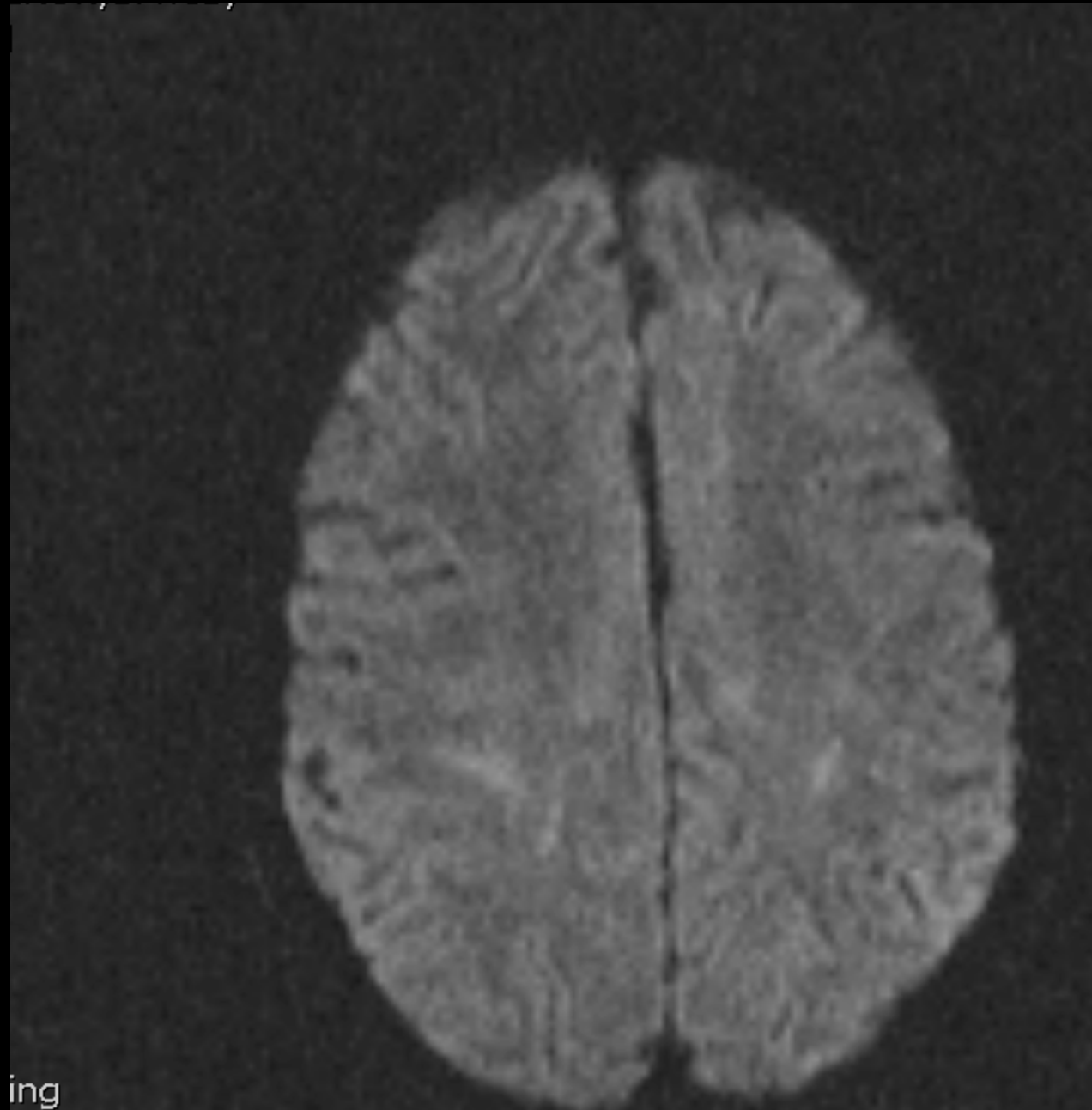
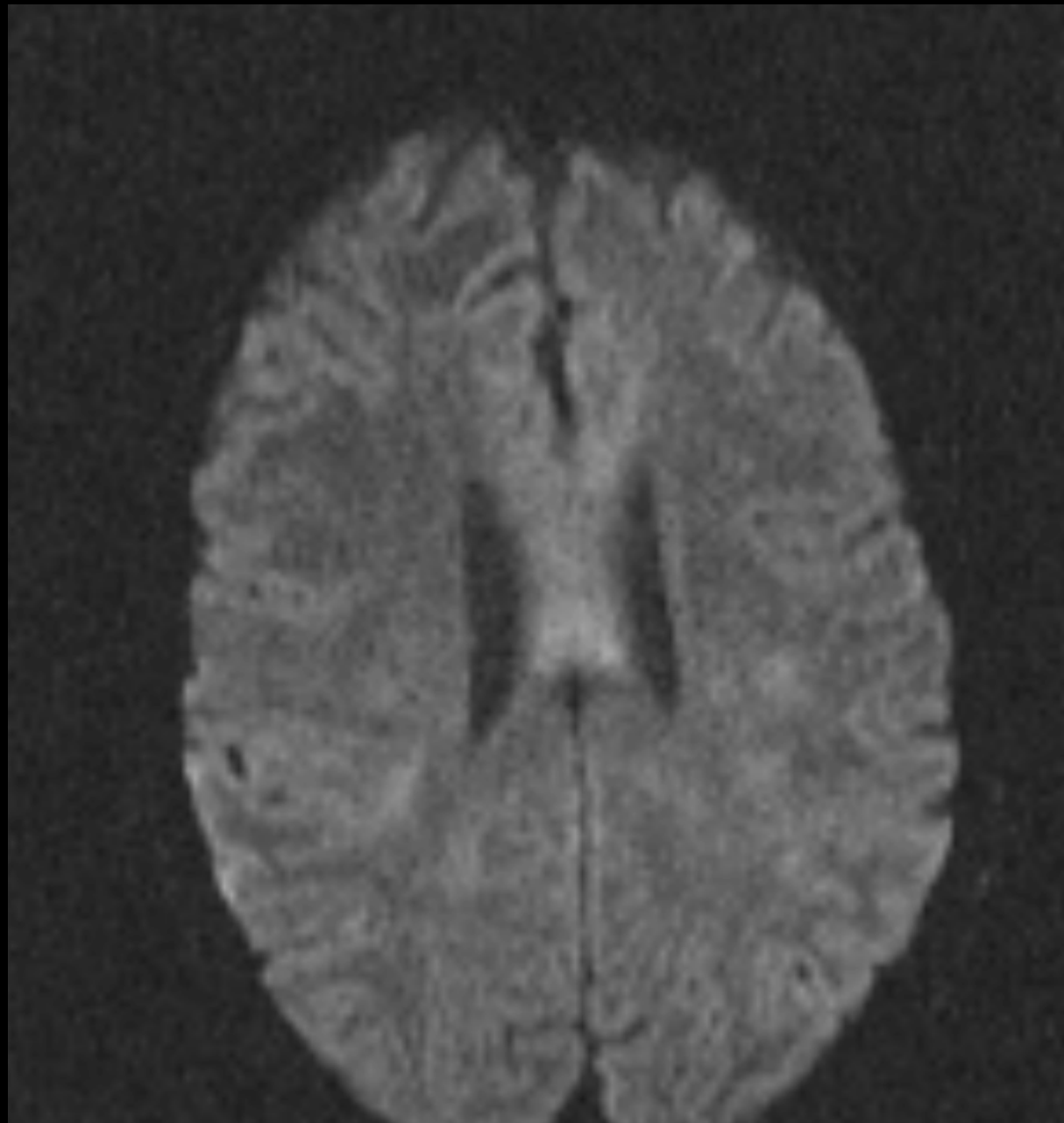
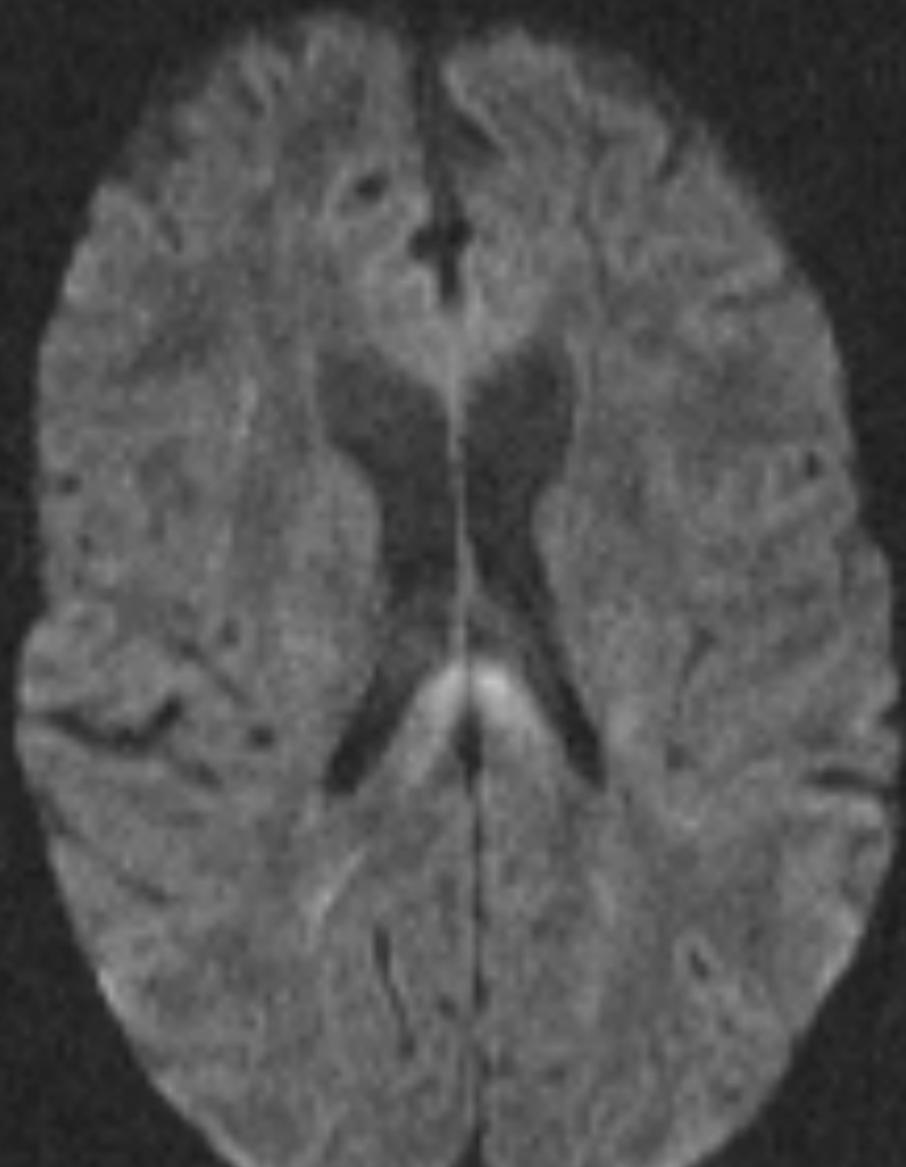


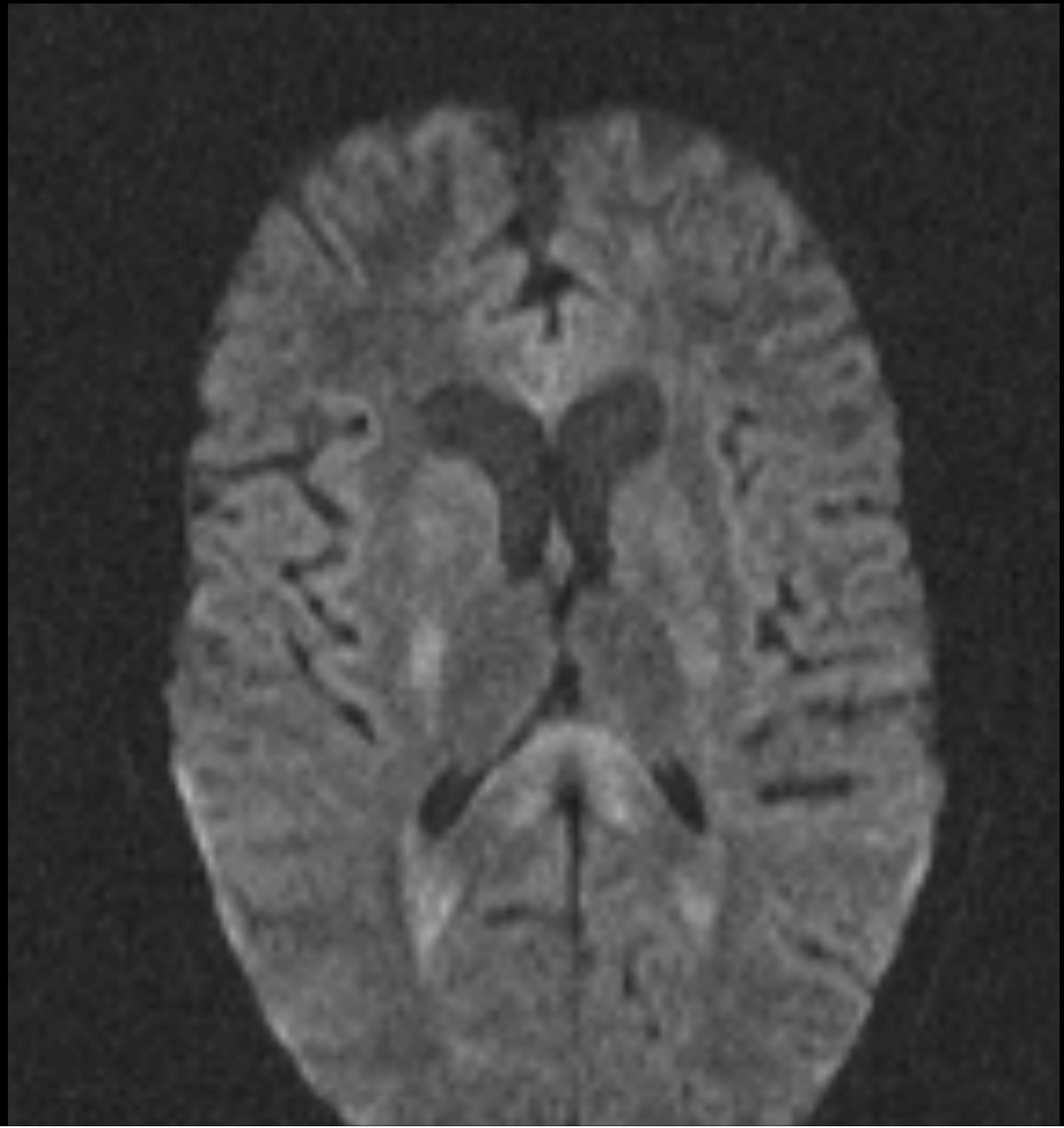
**10 yr old boy with severe episodic
worsening of choreiform
movement disorder, 'CP', and new
MRI changes**

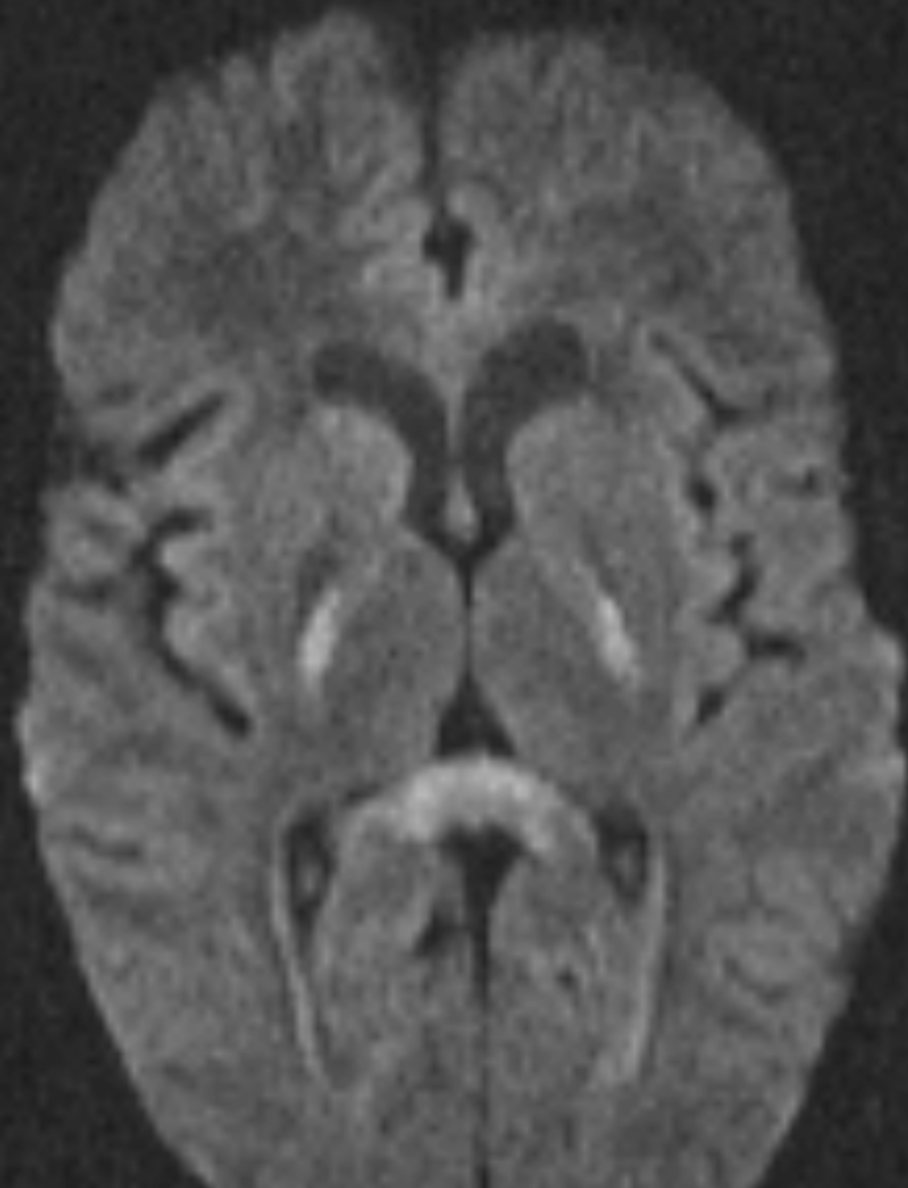


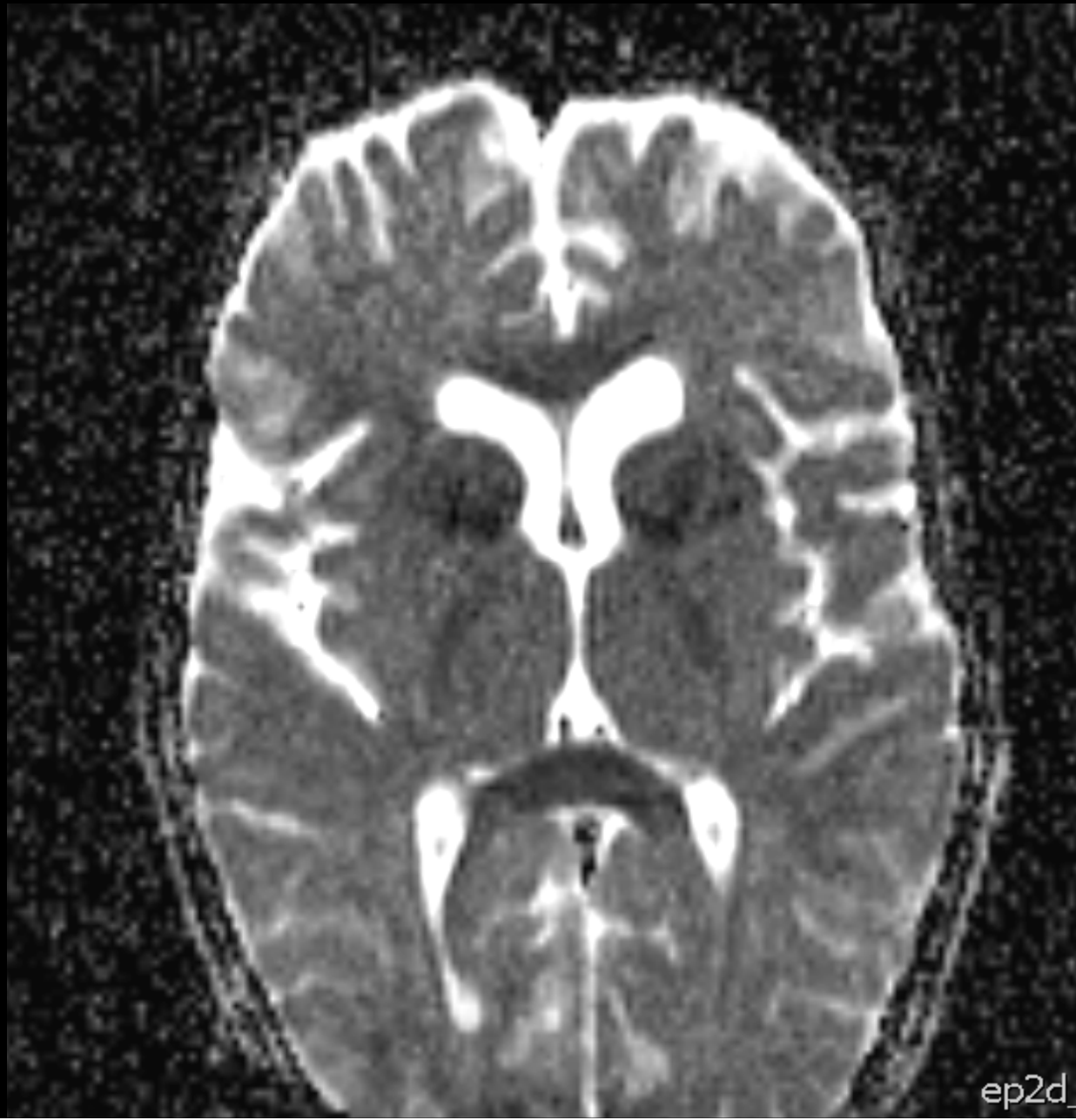
ing



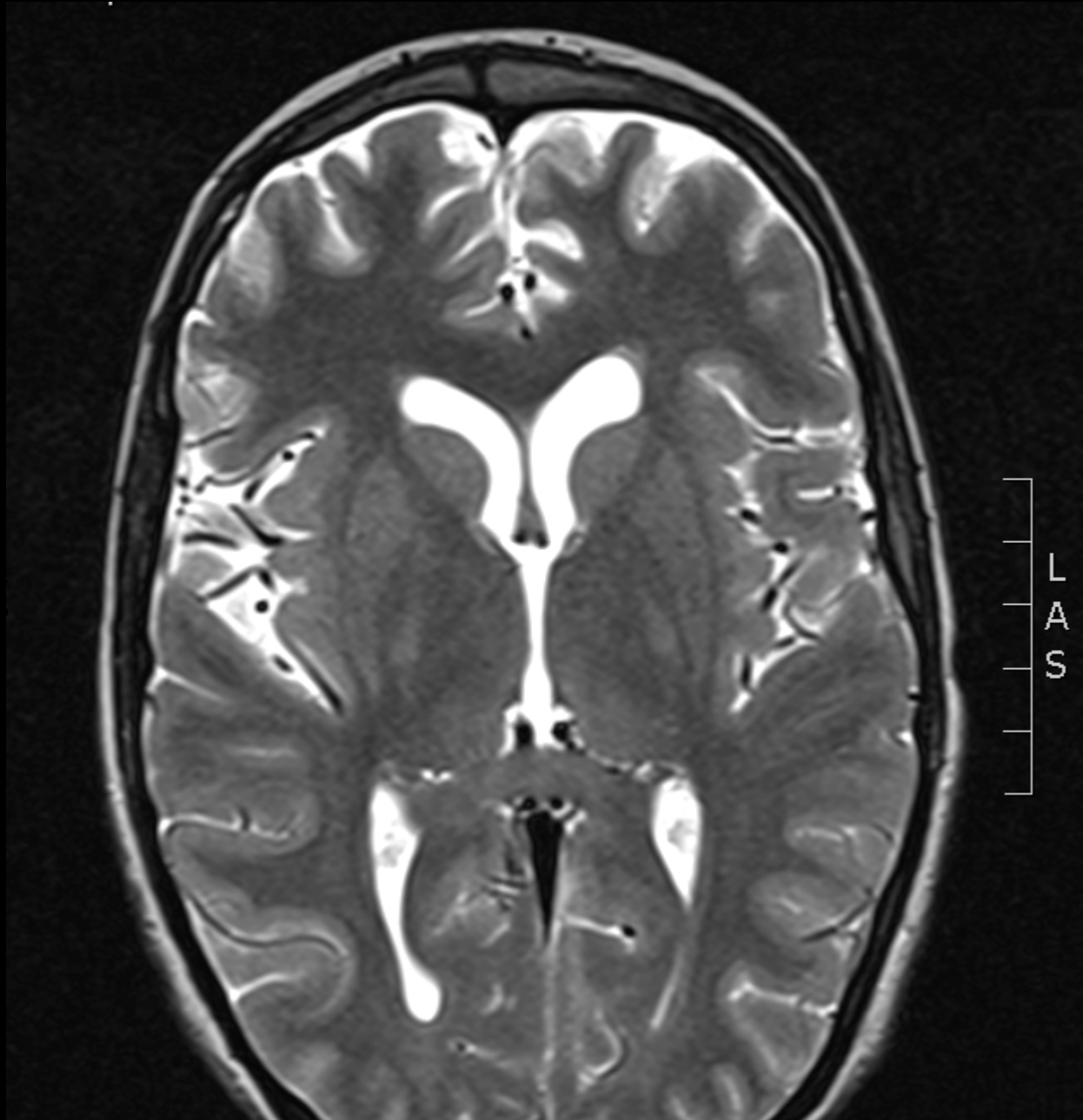


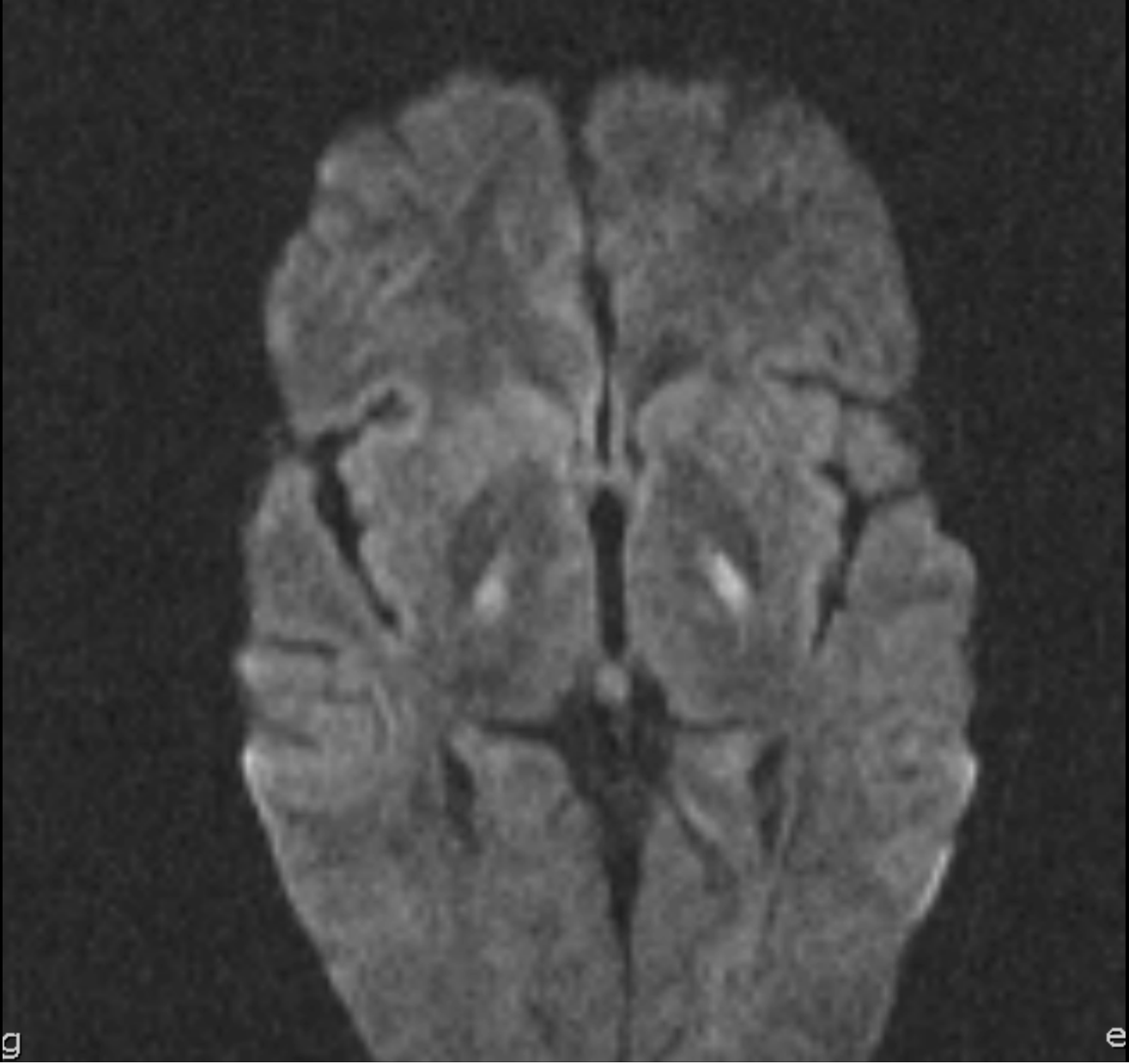






ep2d





d

e

